

## Effect of *Citrus aurantium* Extract on Spermatogenesis in Streptozotocin-Induced Diabetic Rats

**Leili Komeilifard (MSc)**

Department of Biology, Islamic Azad University, Jahrom Branch, Jahrom, Iran

**Vahid Hemayatkhah Jahromi (PhD)**

Department of Biology, Islamic Azad University, Jahrom Branch, Jahrom, Iran

**Corresponding author:** Vahid Hemayatkhah Jahromi

**Email:** Dr.hemayatkhah@yahoo.com

**Tel:** +989177023697

**Address:** Islamic Azad University, Jahrom Branch, Jahrom, Iran

**Received :** 06 Dec 2014

**Revised:** 20 Jul 2014

**Accepted:** 21 Jul 2014

### ABSTRACT

**Background and Objectives:** Diabetes is one of the most common endocrine disorders, which is associated with changes in testicular tissue. The present study investigated therapeutic and prophylactic properties of bitter orange (*Citrus aurantium*) juice on testicular tissue and spermatogenesis process.

**Methods:** Forty streptozotocin-induced diabetic Wistar rats aged three months with mean weight of 170-200 g were divided into 4 groups including 1) control group, 2) diabetic control group, 3) diabetic group receiving 100mg/kg *C. aurantium* extract and 4) diabetic group receiving 200 mg/kg *C. aurantium* extract. The extract was administered to the rats for 56 days by gavage. After this period, the rats were anesthetized with ether and then their testes were fixed in 10% formalin for sample preparation. The testicular tissue was examined by haematoxylin and eosin staining under a light microscope with 10 and 40 magnifications. The mean number of Leydig and Sertoli cells, spermatogonia, spermatocytes and spermatids were calculated.

**Results:** A significant decrease was observed in mean weight of left testis in diabetic rats compared to that of controls ( $P \leq 0.05$ ). The mean weight of testes showed no significant difference in diabetic rats treated with 200 mg/kg of extract compared with the control group. Diabetes reduced the number of spermatogonia, spermatocytes, spermatids and Sertoli cells. The number of cells increased significantly in the diabetic group receiving 200 mg/kg of extract. The spermatocytes and spermatids in both groups treated with the extract increased significantly.

**Conclusion:** This study shows the positive effect of bitter orange extract on complications of diabetes in testicular tissue. Therefore, this extract could be used for therapeutic purposes.

**Keywords:** diabetes, bitter orange juice, spermatogenesis, testis, rat.

## INTRODUCTION

Diabetes mellitus is one the most common endocrine disorders, usually determined by insulin deficiency, insulin dysfunction and decreased insulin sensitivity of tissues. It is accompanied with impaired metabolism of carbohydrates, fats and proteins. It is believed that the disease is caused by complex interactions and genetic, environmental and lifestyle factors (1).

The metabolic regulation disorders caused by diabetes mellitus cause secondary pathological changes that can lead to several problems in patients (2). Tissues such as the brain, retina and kidneys are also at risk, although these tissues are not insulin-dependent for glucose transport. Oxidative stress plays an important role in progression of diabetes mellitus (3). Imbalance between reactive oxygen species or free radicals such as superoxide, hydrogen peroxide and antioxidants produces oxidative stress (4).

Diabetes mellitus have various effects on the reproductive system of males. Reduced testosterone production (5), reduction of the reproductive glands, and (6) declined sex drive (5) and sexual behavior have been reported in people with diabetes. Diabetes also affects spermatogenesis (7). Poor quality of semen including reduced sperm motility, (8) reduced sperm count and increased number of abnormal sperms have been reported in diabetic individuals (9).

Bitter orange or *Citrus aurantium L.* is a tree from the Rutaceae family (10). Flowers, peel and juice of bitter orange are the useable parts that have medicinal properties. This plant is known to have sedative, hypnotic and appetizing effects that can stop heart palpitations (11). This plant is native to tropical Asia including India and China, Spain, South America, Italy, Palestine and some parts of Iran including Fars Province.

Peel of *C. aurantium* contains essential oils, flavonoids, coumarins, triterpenes, vitamin C, carotene and pectin. Flavonoids have anti-inflammatory, antibacterial and antifungal properties (12).

## MATERIAL AND METHODS

Fruit of bitter orange (obtained from the city of Jahrom) were cleaned, dried and ground. Then, 100g of the powdered fruit were mixed with 1000 ml of 50% ethanol in percolator. Extraction was carried out after soaking in ethanol for 72 hours. Excess solvent was

separated using the rotary apparatus to concentrate the mixture. Then, the extract appeared as yellowish brown powder with the help of desiccator and vacuum pump. Overall, 37.8 g of dry substance was obtained from 100 g of bitter orange fruit using the percolation method. First, 40 adult male Wistar rats aged approximately 3 months and weighing 170-200 g were obtained from the School of Medicine, Shiraz. For adopting the rats with the environment, they were kept at  $23\pm 2$  °C and 12:12 day-night cycle for 14 days.

Diabetes was induced in rats by a single dose intraperitoneal injection of 50 mg/kg streptozotocin (STZ) that was dissolved in 0.9% NaCl and 100 mM sodium citrate buffer solution with pH of 4.5 (13).

The blood glucose of subjects was measured with a glucometer before and 7 days after the injection of STZ. For feeding the extract, the syringe was put into the mouth to inject the extract to the esophagus based on body weight and group of subjects.

The rats were divided into 4 groups of 10:

1. Control group: This group did not receive any treatment and only received standard laboratory food and water during the experimental period.
2. Diabetic control group: This group was treated with a single dose of intraperitoneal STZ (50 mg/kg).
3. This diabetics group received 100 mg/kg of bitter orange extract for 56 days by gavage.
4. This diabetic group received 200 mg/kg of bitter orange extract for 56 days by gavage.

After the end of the experiment period, the rats were weighed and anesthetized with ether and finally anatomized. Testicles were separated from the surrounding tissues using scalpel and forceps and then placed in 10% formaldehyde. Then, tissue passage was performed including fixation, dehydration, embedding, sectioning, staining and mounting. After molding, 5-micron thin sections were made by microtome. The sections were later attached to surface of slide using egg albumen adhesive. The slide was stained by hematoxylin and eosin after which the nucleus and the cytoplasm appeared in blue and pink color, respectively. The slides prepared from adult rats testes cross-sections were studied by a light microscope under 40X magnification.

The mean number of spermatogonia, spermatocytes, spermatids, and Sertoli and Leydig cells in 20 seminiferous tubules per slide was calculated by counting under the light microscope. After counting the cells, photographs were taken by a microscope equipped with a Nikon camera. The raw numbers obtained from counting the number of spermatogonia, spermatocytes, spermatids, Leydig and Sertoli cells in different groups were analyzed and compared in SPSS software using one way ANOVA and post-hoc Duncan's test. Graphs were plotted using the Microsoft Excel software. The values were presented as mean  $\pm$  standard error of the mean (SEM). P-values less than 0.05 were considered as statistically significant.

## RESULTS

The mean level of blood glucose in the groups treated with the extract reduced significantly compared to the diabetic group ( $P < 0.05$ ). In addition, a significant reduction was observed in the mean weight of left testicle of diabetic rats compared to the controls. However, no significant difference was found between the mean weight of testis of rats receiving 200

mg/kg extract and that of the control group (Table 1). The mean number of spermatogonia cells reduced significantly in the diabetic group but increased in the groups treated with 100 and 200 mg/kg of extract compared to the diabetic group. However, this increase was significant only in the diabetic group receiving 200 mg/kg.

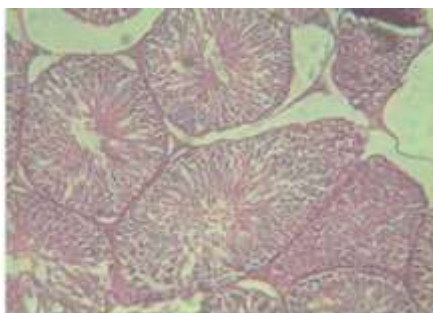
A significant reduction was found in the mean number of spermatocytes and spermatids in the diabetic group compared to the control group. However, the mean number of these cells increased significantly in the groups treated with the extract compared to diabetic group (Table 1).

Moreover, a significant reduction was found in the mean number of Leydig and Sertoli cells in all diabetic groups compared to the control group. The number of Sertoli cells increased in the groups receiving 100 and 200 mg/kg of extract compared to the diabetic group. However, this increase was not statistically significant. The number of Leydig cells did not show a significant increase in the diabetic groups receiving doses of the extract compared to the diabetic group.

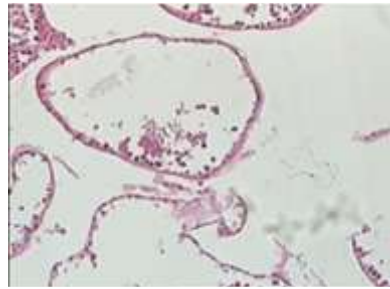Table 1- Comparison of testicular weight and number of spermatogenic cells of rats (mean  $\pm$  SD)

Spermatid	Spermatocytes	Spermatogonia	Sertoli cells	Leydig cells	Testicular weight (g)	Groups
a 208/69 $\pm$ 9/14	a 131/99 $\pm$ 6/43	a 87/19 $\pm$ 2/63	a 26/72 $\pm$ 4/77	a 26/72 $\pm$ 4/77	a 1/53 $\pm$ 0/03	Control
b 19/81 $\pm$ 10/78	b 7/91 $\pm$ 0/97	b 22/05 $\pm$ 1/32	b 3/28 $\pm$ 1/35	b 3/28 $\pm$ 1/35	b 0/80 $\pm$ 0/11	Diabetic
bc 39/16 $\pm$ 3/76	c 37/60 $\pm$ 7/33	b 36/91 $\pm$ 8/42	b 4/1 $\pm$ 1/03	b 4/1 $\pm$ 1/03	b 1/08 $\pm$ 0/16	Diabetic + 100 mg/kg extract of bitter orange
c 84/71 $\pm$ 32/24	d 71/69 $\pm$ 10/85	c 64/69 $\pm$ 5/31	b 9/02 $\pm$ 4/23	b 9/02 $\pm$ 4/23	ab 1/19 $\pm$ 0/21	Diabetic + 200 mg/kg extract of bitter orange

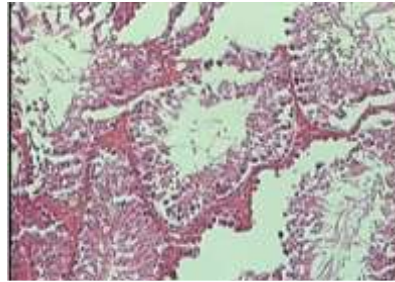
Figure 1- Tubules and normal germ cells in the control group



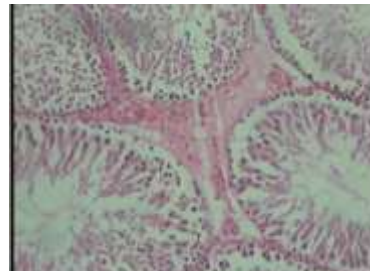
**Figure 2- Increase in the intratubular space and decrease in number of germ cells in the diabetic group**



**Figure 3- Decrease in the interstitial space and prevention of germ cells elimination by 100 ml of bitter orange extract**



**Figure 4- Significant reduction in the interstitial space and complete recovery of germ cells by 200 ml of bitter orange extract**



## DISCUSSION

Nowadays, consumption of synthetic drugs has increased due to their positive effects. However, production problems, high cost and side effects of these drugs have made the use of medicinal plants and traditional medicine more common among people. Diabetes mellitus is a metabolic disorder characterized by abnormally high levels of glucose that could be a main cause of death in the world in the future (1).

Studies indicate that most of the energy is supplied by metabolism of sugar and fat. Any factor that affects glucose metabolism indirectly affects fat metabolism (14), and reduced insulin leads to weight loss (15). Studies have shown that weight of testis and secondary organs decrease in diabetic rats compared to normal rats (16), which is consistent with the results of the present study. Testicular weight is associated with the number of Sertoli cells and spermatogenesis (17, 18), while the size of testis reflects the

number of germ cells (17). Diabetes mellitus causes changes in testicular tissue through cell death, reduction in the diameter of the seminiferous tubules and reduction in the collection of spermatogenic cells (19, 20). Consuming 100 and 200 mg/kg of bitter orange extract improve spermatogenesis (Table 1 and Figure 2). In the group receiving 100 mg/kg extract, the interstitial space reduced compared to the diabetic group and prevented the destruction of germ cells. However, the tubules still had wrinkles and recovery of tubules has not been completed (Figure 3). In the group receiving 200 mg/kg of extract, the interstitial space reduced significantly compared to diabetic group and prevented the destruction of germ cells, indicating the effectiveness of bitter orange extract (Figure 4). Studies also showed that pomegranate juice increases the thickness of germinal cells and density of spermatogenic

cells in diabetic rats due to its antioxidant properties (21).

## CONCLUSION

The findings of this study show that the amniotic membrane-derived MSCs of NMRI mouse can differentiate into hepatocyte-like cells under the influence of the liver extract.

## REFERENCES

- Xu YQ, Liu ZC. *Therapeutic potential of adult bone marrow stem cells in liver disease and delivery approaches*. Stem cell reviews. 2008; 4(2): 101-12. doi: 10.1007/s12015-008-9019-z.
- Baksh D, Song L, Tuan R. *Adult mesenchymal stem cells: characterization, differentiation, and application in cell and gene therapy*. Journal of cellular and molecular medicine. 2004; 8(3): 301-16. PMID:15491506.
- Pournasr B, Farzaneh Z, Shahsanvani M, Baharvand H. *Liver development and in vitro differentiation of embryonic stem cells to hepatocytes*. Yakhteh Medical Journal. 2010; 11(4): 348-73. [persian]
- Banas A, Yamamoto Y, Teratani T, Ochiya T. *Stem cell plasticity: learning from hepatogenic differentiation strategies*. Developmental Dynamics. 2007; 236(12): 3228-41.
- Teramoto K, Asahina K, Kumashiro Y, Kakinuma S, Chinzei. *Hepatocyte differentiation from embryonic stem cells and umbilical cord blood cells*. Journal of hepatobiliary-pancreatic surgery. 2005; 12(3): 196-202. PMID:15995807.
- Sugaya K. *Potential use of stem cells in neuroreplacement therapies for neurodegenerative diseases*. International review of cytology. 2003; 228: 1-30. PMID:14667041
- Chapel A BJ, Bensidhoum M, Fouillard L, Young RG, Frick J, Demarquay C, et al. *Mesenchymal stem cells home to injured tissues when co-infused with hematopoietic cells to treat a radiation-induced multi-organ failure syndrome*. The journal of gene medicine. 2003; 5(12):1028-38.
- Lee OK, Kuo TK, Chen W-M, Lee K-D, Hsieh S-L, Chen T-H. *Isolation of multipotent mesenchymal stem cells from umbilical cord blood*. Blood. 2004; 103(5): 1669-75. PMID:14576065
- Vater C, Kasten P, Stiehler M. *Culture media for the differentiation of mesenchymal stromal cells*. Acta biomaterialia. 2011; 7(2): 463-77. doi: 10.1016/j.actbio.2010.07.037.
- Mafi R, Hindocha S, Mafi P, Griffin M, Khan W. *Suppl 2: Sources of Adult Mesenchymal Stem Cells Applicable for Musculoskeletal Applications-A Systematic Review of the Literature*. The open orthopaedics journal. 2011; 5: 242. doi: 10.2174/1874325001105010242.
- Bunnell BA, Flaatt M, Gagliardi C, Patel B, Ripoll C. *Adipose-derived stem cells: isolation, expansion and differentiation*. Methods. 2008; 45(2): 115-20. doi: 10.1016/j.ymeth.2008.03.006.

## ACKNOWLEDGMENTS

This study was based on an approved project (No 41/91) funded by the Lorestan University of Medical Sciences. The authors would like to express their gratitude for authorities of the university.

## CONFLICT OF INTEREST

The authors declare no conflict of interest

- Parolini O, Alviano F, Bergwerf I, Boraschi D, De Bari C, De Waele P, et al. *Toward cell therapy using placenta-derived cells: disease mechanisms, cell biology, preclinical studies, and regulatory aspects at the round table*. Stem cells and development. 2010;19(2): 143-54. doi: 10.1089/scd.2009.0404.
- Zhang Y, Li C, Jiang X, Zhang S, Wu Y, Liu B, et al. *Human placenta-derived mesenchymal progenitor cells support culture expansion of long-term culture-initiating cells from cord blood CD34+ cells*. Experimental hematology. 2004; 32(7): 657-64.
- Solomon A, Wajngarten M, Alviano F, Anteby I, Elchalal U, Pe'er J, et al. *Suppression of inflammatory and fibrotic responses in allergic inflammation by the amniotic membrane stromal matrix*. Clinical & Experimental Allergy. 2005; 35(7): 941-8.
- Ilancheran S, Michalska A, Peh G, Wallace EM, Pera M, Manuelpillai U. *Stem cells derived from human fetal membranes display multilineage differentiation potential*. Biology of reproduction. 2007; 77(3): 577-88.
- Marongiu F, Gramignoli R, Sun Q, Tahan V, Miki T, Dorko K, et al. *Isolation of amniotic mesenchymal stem cells*. Current protocols in stem cell biology:1E. 5.1-E. 5.11.
- NematiSh BH. *Differentiation of human bone marrow mesenchymal stem cells to neural-like cells in vitro*. Tehran University Medical Journal Nov 2009; Vol. 67, No. 8 .527-534.
- Eslaminejad MB, Nikmahzar A, Taghiyar L, Nadri S, Massumi M. *Murine mesenchymal stem cells isolated by low density primary culture system*. Development, growth & differentiation. 2006; 48(6): 361-70.
- Solati Sarvandi S, Joghataei MT, Parivar K, Khosravi M, Sarveazad A, Sanadgol N. *In vitro differentiation of rat mesenchymal stem cells to hepatocyte lineage*. Iran J Basic Med Sci. 2015; 18: 89-97.
- Raoufi A, Amini A, Azadbakht M, Abouzari M. *In vitro differentiation of human umbilical vein mesenchymal stem cells into hepatocyte-like cells identified by cellular uptake of indocyanine green*. Khoon. 2010; 7(1): 34-40. [Persian]
- Ko O, Gerson S, Cooper B, Dyhouse S, Haynesworth S, Caplan A, et al. *Rapid hematopoietic recovery after confusion of autologous-blood stem cells in advanced breast cancer patients receiving high dose chemotherapy*. J Clin Oncol. 2000; 18(2): 307-16.
- Petite H, Viateau V, Bensaid W, Meunier A, de Pollak C, Bourguignon M, et al. *Tissue-engineered bone regeneration*. Nature biotechnology. 2000; 18(9): 959-63.

23. Quarto R, Mastrogiacomo M, Cancedda R, Kutepov SM, Mukhachev V, Lavroukov A, et al. *Repair of large bone defects with the use of autologous bone marrow stromal cells*. New England Journal of Medicine 2001;344(5):385-6.
24. Grinnemo K, Mansson A, Dellgren G, Klingberg D, Wardell E, Drvota V, et al. *Xenoreactivity and engraftment of human mesenchymal stem cells transplanted into infarcted rat myocardium*. The Journal of thoracic and cardiovascular surgery. 2004; 127(5): 1293-300. PMID:15115985.
25. Horwitz EM GP, Koo WK, Marx JC, NeelMD,mcNallRY,Muull,Hofmann T. *Isolated allogenicbone marrow- drivenmesenchymal cells engraftand stimulate growth in children with osteogenesisimperfecta: Implications for cell therapy of bone*. Proc Natl Acad Sci USA. 2002; 99: 8932-37.
26. Niknejad H, Peirovi H, Ahmadiani A, Ghanavi J, Jorjani M. *Differentiation Factors That Influence Neuronal Markers Expression In Vitro From Human Amniotic Epithelial Cells*. Eur Cell Mater. 2010; 19: 22-9.